



## Case Report

### Wound Healing Therapy With a 650-Microsecond 1064nm Laser

Aletha W. Tippett\*

Family Medicine Physician, Wound Care Specialist with WCC, Medical Director Brookdale Hospice in Dayton, Ohio, USA

\***Corresponding author:** Aletha W. Tippett, Family Medicine Physician, Wound Care Specialist with WCC, Brookdale Hospice in Dayton, Ohio, USA. Tel: +15134848605; Email: tippettaw@fuse.net

**Citation:** Tippett AW (2018) Wound Healing Therapy With a 650-Microsecond 1064nm Laser. J Family Med Prim Care Open Acc: JFOA-120. DOI: 10.29011/JFOA-120. 100020

**Received Date:** 16 July, 2018; **Accepted Date:** 31 July, 2018; **Published Date:** 07 August, 2018

#### Abstract

**Objective:** The objective of this paper is to present observational data to support the premise of using a 650-microsecond Nd:YAG 1064 nm laser for wound healing.

**Background:** Laser light treatment has been reported to stimulate collagen production, the primary reason lasers are useful for cosmetic procedures such as reducing wrinkles and smoothing skin lines [1,2]. This ability to stimulate collagen, the main protein involved in wound healing, provokes the idea that a cosmetic laser could be used to promote wound healing. When working with chronic wounds, one of the main goals is to stimulate dermo-fibroblast synthesis of collagen. A demonstrated way to do this is by serial debridements, plus there are many biotech products are on the market that attempt to aid in this, in addition to, or instead of, serial debridements of the wound [3]. Cold laser therapy has actually been used for years to stimulate wound healing, but the technology has not been widely applied [3]. There have been a number of published articles on using lasers for wound healing [4-6]. Most of these use low level lasers, not cosmetic lasers, but there have been several published studies using Nd: YAG lasers for wound healing [7-9]. Multiple types of laser have been tried, especially for diabetic wound healing and have found low-energy is helpful but more research is needed [10]. The consensus from published articles is that low level laser therapy in the range of 4-8 joules/cm<sup>2</sup> is beneficial for wound healing. Some practitioners are seeing results using multiple passes with 11 joules, but there is some study that higher laser power can be harmful to a wound by inducing scarring [7,8,11]. Having a non-invasive simple method that predictably will promote wound healing would be a boon to the millions of people suffering from various chronic wounds and for their caregivers trying to heal these wounds.

#### Case Report

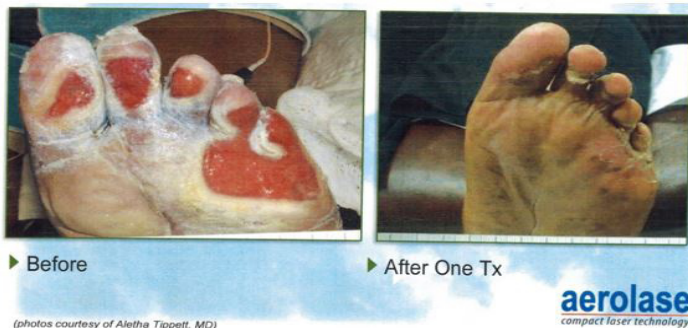
The 650-microsecond Nd:YAG 1064 nm laser has been used by this writer for over 10 years for a variety of purposes, including wound stimulation. The Nd:YAG is a cosmetic laser and certainly can be used for a variety of purposes: hair removal, skin rejuvenation, scar reduction, wrinkle removal, lesion ablation, acne, etc. This laser, made by Aerolase, has a unique 650-microsecond pulse duration which enables the pulse to be delivered in a collimated beam, so that skin contact by the handpiece is not necessary (as it is with other lasers), and also it has the ability to dial in the fluence used, down all the way to 4 joules/cm<sup>2</sup> at the lowest setting. In 2006 a report was made of using this laser on 17 wound patients over 10 weeks. All patients were treated with 4 joules/cm<sup>2</sup>, single pass. Patients were treated at various intervals. Overall, 11 or 65% of wounds improved, 3 or 18% had no change, 1 patient was lost to follow-up and 1 patient had increased pain with no improvement in the wound. A variety of wounds were treated, including pressure, neuropathic, radiation fibrosis, and burns. This retrospective look

at the use of the 650-microsecond Nd:YAG 1064 nm laser for wound healing would indicate it could be an effective adjunctive instrument and deserves further study.

The level of risk in doing this procedure is minimal. Proper eye protection is worn when using the laser. Laser fluence used is very low, at which level most people cannot even feel it, also there is no contact at all to the skin by the handpiece and no numbing or cooling gels that are common with most cosmetic lasers. There would be no injury or bleeding. There is no anticipated discomfort associated with the laser treatment. The anticipated benefit justifies the minimal risk involved. The 650-microsecond Nd:YAG laser could become a useful adjuvant in wound care, plus open the possibility of more studies to determine the ideal fluence to use.

Because of previous preliminary work it is anticipated that patient's wounds would heal faster than they would with available alternative approaches. Laser therapy using low fluence of 4 joules/cm<sup>2</sup> in one pass was used on patients with wounds. Two of these are shown here below.

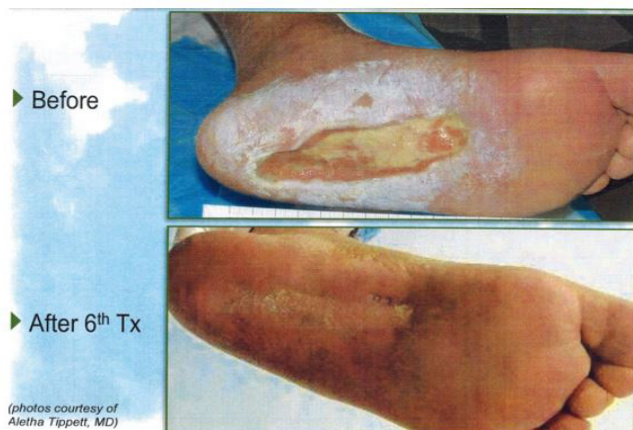One was a 37-year-old diabetic woman with burns on her feet. Because of her peripheral neuropathy she could not feel the burns when she slept with a heater. Interesting that she had seen five physicians who all told her foot needed amputation. She saw me and after taking a history, I determined she had burns and treated them appropriately. I did use the laser on her wounds and the pictures below show the beginning and after treatment. Laser therapy dramatically improved her wounds. Her wounds healed completely without scarring and one could not tell that she ever had the wounds (Figure 1).



(photos courtesy of Aletha Tippet, MD)

**Figure 1:** Laser on her wounds show treatment sites before and after treatment.

A second patient was a 65-year-old man with diabetes who was diagnosed with gas gangrene of the foot and was scheduled in the hospital for amputation. I met the surgeon outside the OR and begged him to do a wide debridement instead of amputation. He agreed and did a wide debridement of the foot. The next day I started treating the wound - we did use laser therapy once a week for six weeks and the pictures of beginning and after 6 weeks are shown here. Clearly the laser facilitated the healing and closure of his wound. This patient went on to totally heal his wound and was ambulatory and in fact went on a family vacation to Florida shortly thereafter (Figure 2).



**Figure 2:** Laser therapy before therapy and after 6 weeks.

Why do some wounds respond better to laser therapy than others? This is unknown by this author. Certainly burns do well and that has been seen with other burns as well. Acne responds very well to laser, but that is beyond the scope of this paper. Pressure ulcers have all responded well, but not if with radiation fibrosis. The one surgical wound presented here did well, but took six treatments. It is not clear if the area of body impacts response to laser.

## Conclusion

Clearly it appears that use of laser (650-microsecond Nd:YAG 1064 nm) can help wound healing, and based on this clinical cases wound closure is substantially facilitated as compared to purely non-laser therapy. Giving it a trial is highly recommended. Low dose, 4 joules/cm<sup>2</sup> seems to work very well and I would be resistant to trying higher doses as stated above. Use of this cosmetic laser for wound healing deserves further investigation.

## References

1. Huang YY, Chen AC, Carroll JD, Hamblin MR (2009) Biphasic dose response in low level light therapy. *Dose Response* 7: 358-383.
2. Capon A, Mordon S (2003) Can thermal lasers promote skin wound healing? *Am J Clin Dermatol* 4: 1-12.
3. Cardinal M, Eisenbud DE, Armstrong DG, Zelen C, Driver V, et al. (2009) Serial surgical debridement: a retrospective study on clinical outcomes in chronic lower extremity wounds. *Wound Repair Regen* 17: 306-311.
4. Demir H, Yaray S, Kirnap M, Yaray K (2004) Comparison of the effects of laser and ultrasound treatments on experimental wound healing in rats. *J Rehabil Res Dev* 41: 721-728.
5. Hopkins JT, McLoda TA, Seegmiller JG, Baxter GD (2004) Low-level laser therapy facilitates superficial wound healing in humans: A triple-blind, sham-controlled study. *J Athl Train* 39: 223-229.
6. Al-Watban FA, Zhang XY, Andres BL (2007) Low-level laser therapy enhances wound healing in diabetic rats: A Comparison of different lasers. *Photomed Laser Surg* 25: 72-77.
7. Romanos GE, Pelekanos S, Strub JR (1995) Effects of Nd:YAG laser on wound healing processes: Clinical and immunohistochemical findings in rat skin. *Lasers Surg Med* 16: 368-379.
8. Romanos GE, Pelekanos S, Strub JR (1995) A comparative histological study of wound healing following Nd:YAG laser with different energy parameters and conventional surgical incision in rat skin. *J Clin Laser Med Surg* 13: 11-16.
9. Castro DJ, Abergel RP, Johnston KJ, Adomian GE, Dwyer RM, et al. (1983) Wound healing: Biological effects of Nd:YAG laser on collagen metabolism in pig skin in comparison to thermal burn. *Ann Plast Surg* 11: 131-140.
10. Joe Hurley (2013) Personal communication. Aerolase.
11. Forney R, Mauro T (1999) Using lasers in diabetic wound healing. *Diabetes Technol Ther* 1: 189-192.