Aerolase® LightPod Era®

Clinical Insights

# Partial-Face Laser Resurfacing with a 300-microsecond Pulsed Er:YAG 2940nm Laser

**Allen Rosen, M.D.,**
Medical Director, The Plastic Surgery Group
Assistant Clinical Professor,
University of Medicine and Dentistry of New Jersey

## Abstract

This study was conducted to evaluate the effect of 300 microsecond pulsed Er:YAG 2940nm laser resurfacing on periocular lines, treated as a functional unit based on static and dynamic rhytid anatomy as opposed to standard cosmetic anatomic landmarks. Over a three year period of time, 14 female patients, with Fitzpatrick skin type II-III were treated with Erbium laser resurfacing to the periocular area based on a pattern consistent with their static and dynamic "crow's feet" lines versus standard anatomic units. Improvement in periocular rhytids was achieved efficiently using Erbium laser resurfacing based on functional landmarks without the need to treat adjacent uninvolved areas within the aesthetic unit based on anatomical landmarks alone.

## Background and Objectives

Standard published aesthetic units of the face generally based on anatomic landmarks have been valuable for surgeons performing facial rejuvenation surgery and deeper laser resurfacing, since it provided a context for treatment zones in keeping with consistent pleasing facial patterns. Meanwhile, conventional $CO_2$ and Erbium resurfacing required full-face treatment to avoid demarcation lines, which have been associated with collateral thermal damage in the dermis. But Erbium laser resurfacing with a novel 300 microsecond pulsed Er:YAG 2940nm laser has been shown to have a greater safety profile with regard to pigmentary changes following superficial resurfacing, and for that reason, we began treating patients based on their functional anatomy in the periocular area rather than standard aesthetic unit landmarking. This approach was intended to treat only the affected areas of the crow's feet (both static and dynamic) without needing to treat uninvolved adjacent areas within the standard published aesthetic unit. The objective was to obtain a quicker, more efficient, and focused approach to the treatment of fine lines and wrinkles of the periocular area.

## Study Design/Materials and Methods

Fourteen consecutive female patients, ages 40 to 75 with median age of 53 years old, were marked for treatment in the periocular area, both in the standard nonsmiling and functional smiling positions. All patients were Fitzpatrick skin type II or III and were treated in a single session with the Erbium laser (Aerolase, Tarrytown, New York) with three sequential passes starting at 3.0, 4.0, and 5.0 joules/cm$^2$ respectively over the functionally landmarked areas of crow's feet. Standard cleansing of the eschar between passes was performed. No subjects were on Accutane or contraindicated medications prior to or during the course of treatment. The skin was prepared with a standard exfoliation regimen, and they were all pretreated with topical anesthetic cream. Laser spot size was approximately 3-4mm. Feathering of the edges of the aesthetic unit was performed via 45° angulation of the laser spot. Posttreatment care included standard cleansing and moisturization regimen.

## Results

Functional mapping of rhytidosis for treatment with Erbium laser was effective in eliminating rhytides and achieving a high degree of patient satisfaction without the need for treatment of unaffected areas of the adjacent anatomic aesthetic unit with proper feathering of edges. We demonstrated that efficient, effective, and focused attention, of the affected dynamic and static fine line wrinkles of the periocular area eliminated the need for treatment of uninvolved adjacent skin.

## Conclusion

This small series confirms many previous reports of the safety and efficacy of superficial ablative resurfacing with Erbium laser in the periocular area. It further presents evidence that functional landmarking with feathering technique is effective in treating areas of skin rhytidosis and suggests it is not necessary to treat uninvolved skin within the anatomic aesthetic unit, to obtain comparable results. We believe that the lack of significant pigmentary changes associated with 300 microsecond pulsed Erbium laser resurfacing allows for selective treatment of periocular rhytidosis on a functional rather than anatomic bases.

# Aerolase® LightPod Era®

# Clinical Insights

Before

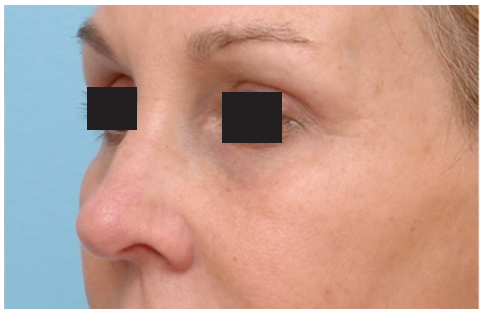

After One Tx

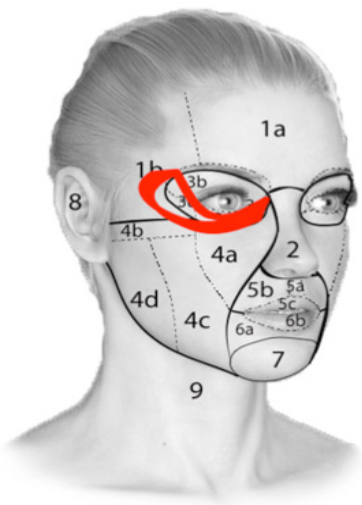


Functional Aesthetic Unit

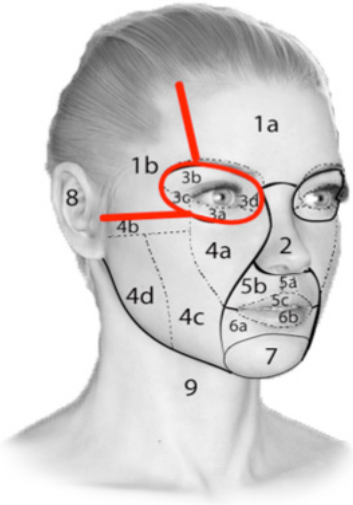


Anatomic Unit

## Q&A with Dr. Allen Rosen

Q:) What led you initially to purchase the LightPod Era?

A:) A gentle modality for skin resurfacing was a glaring hole in our suite of services. We only had chemical peels, which are inconsistent, or $CO_2$ resurfacing, which is aggressive and costly to the practitioner.

Q:) What are the primary treatments for which have you been using the Era?

A:) We primarily use it for periocular and perioral skin resurfacing. Usually only a single treatment is performed, but we tend to provide one or two annual maintenance treatments.

Q:) Are you combining the Era treatments with other modalities?

A:) Yes, we always provide multi-modal treatments. For example, with wrinkles in the forehead and crow's feet areas, we frequently treat with an injectable toxin first and then Era resurfacing afterward the muscles have been disabled by the toxin.

Q:) Are you using any specific techniques?

A:) Yes. Because the LightPod Era does not leave demarcation lines, it is possible to ablate partial areas of the face. For example, when treating crow's feet I treat along the specific wrinkle line – something that I call a 'functional unit' – and feather around it, but I don't need to treat the entire anatomic unit. Leaving that extra skin untreated is beneficial both in terms of reducing procedure time and minimizing the healing for the patient.

Q:) What else is included in the protocol?

A:) Aquaphor is applied to the treatment areas after the procedure. However I have found that I don't need to prescribe antivirals such as Valtrex with each patient, so I have discontinued that.

Q:) Do you have any other feedback about the LightPod Era laser?

A:) Yes. The LightPod Era is a compact and cost-effective system that doesn't take up a lot of space and allows me to offer a uniquely gentle approach to skin resurfacing. It enables me to compete with other practices and specialties, yet with a lot less investment and less training required. This is ideal since my practice is mostly a surgical practice, with less emphasis on laser services.

*Dr. Rosen is Board Certified by the American Board of Plastic Surgery and is the founding partner and medical director of the Plastic Surgery Group. For over a decade he has been a distinguished spokesperson for the American Society of Plastic and Reconstructive Surgeons, and has been recognized as one of our country's premier plastic surgeons for ten years running through peer surveys by Castle Connolly Medical. He has owned the LightPod Era laser since mid 2007.*




aerolase®
reinventing medical lasers